



WHO Classification of Bone Tumours

Primary neoplasms of the skeleton are rare, amounting to only 0.2% of the overall human tumour burden. However, children are frequently affected and the aetiology is largely unknown.

Significant progress has been made in the histological and genetic typing of bone tumours. Furthermore, advances in combined surgical and chemotherapy have led to a significant increase in survival rates even for highly malignant neoplasms, including osteosarcoma and Ewing sarcoma.

Several bone tumours occur in the setting of inherited tumour syndromes, but their histology differs little from the respective sporadic counterparts.

WHO classification of bone tumours

CARTILAGE TUMOURS

Osteochondroma	9210/0*
Chondroma	9220/0
Enchondroma	9220/0
Periosteal chondroma	9221/0
Multiple chondromatosis	9220/1
Chondroblastoma	9230/0
Chondromyxoid fibroma	9241/0
Chondrosarcoma	9220/3
Central, primary, and secondary	9220/3
Peripheral	9221/3
Dedifferentiated	9243/3
Mesenchymal	9240/3
Clear cell	9242/3

OSTEOGENIC TUMOURS

Osteoid osteoma	9191/0
Osteoblastoma	9200/0
Osteosarcoma	9180/3
Conventional	9180/3
chondroblastic	9181/3
fibroblastic	9182/3
osteoblastic	9180/3
Telangiectatic	9183/3
Small cell	9185/3
Low grade central	9187/3
Secondary	9180/3
Parosteal	9192/3
Periosteal	9193/3
High grade surface	9194/3

FIBROGENIC TUMOURS

Desmoplastic fibroma	8823/0
Fibrosarcoma	8810/3

FIBROHISTIOCYTIC TUMOURS

Benign fibrous histiocyoma	8830/0
Malignant fibrous histiocyoma	8830/3

EWING SARCOMA/PRIMITIVE NEUROECTODERMAL TUMOUR

Ewing sarcoma	9260/3
---------------	--------

HAEMATOPOIETIC TUMOURS

Plasma cell myeloma	9732/3
Malignant lymphoma, NOS	9590/3

GIANT CELL TUMOUR

Giant cell tumour	9250/1
Malignancy in giant cell tumour	9250/3

NOTOCHORDAL TUMOURS

Chordoma	9370/3
----------	--------

VASCULAR TUMOURS

Haemangioma	9120/0
Angiosarcoma	9120/3

SMOOTH MUSCLE TUMOURS

Leiomyoma	8890/0
Leiomyosarcoma	8890/3

LIPOGENIC TUMOURS

Lipoma	8850/0
Liposarcoma	8850/3

NEURAL TUMOURS

Neurilemmoma	9560/0
--------------	--------

MISCELLANEOUS TUMOURS

Adamantinoma	9261/3
Metastatic malignancy	

MISCELLANEOUS LESIONS

Aneurysmal bone cyst	
Simple cyst	
Fibrous dysplasia	
Osteofibrous dysplasia	
Langerhans cell histiocytosis	9751/1
Erdheim-Chester disease	
Chest wall hamartoma	

JOINT LESIONS

Synovial chondromatosis	9220/0
-------------------------	--------

* Morphology code of the International Classification of Diseases for Oncology (ICD-O) {726} and the Systematized Nomenclature of Medicine (<http://snomed.org>). Behaviour is coded /0 for benign tumours, /1 for unspecified, borderline or uncertain behaviour, /2 for in situ carcinomas and grade III intraepithelial neoplasia, and /3 for malignant tumours.

WHO classification of tumours of bone: Introduction

H.D. Dorfman
B. Czerniak
R. Kotz

D. Vanel
Y.K. Park
K.K. Unni

Among the wide array of human neoplasms, primary tumours of bone are relatively uncommon. Not only has this contributed to the paucity of meaningful and useful data about the relative frequency and incidence rates of the various subtypes of bone tumours, but it also explains our rudimentary understanding of risk factors.

Little information is available concerning the aetiology and epidemiologic features of benign bone tumours since most published statistical studies have dealt with bone sarcomas. The benign lesions will be considered from the epidemiologic and aetiological standpoint under the individual chapter headings, where they are known.

Incidence

In general, bone sarcomas account for only 0.2% of all neoplasms for which data were obtained in one large series (SEER) {1789}. Comparison of the incidence rate of bone sarcomas with that of the closely related group of soft tissue sarcomas indicates that osseous neoplasms occur at a rate approximately one tenth that of their soft tissue counterparts {537,946,1304}.

In North America and Europe, the incidence rate for bone sarcomas in males is approximately 0.8 new cases per 100,000 population and year. Somewhat higher incidence rates have been observed for males in Argentina and Brazil (1.5-2) and Israel (1.4) {1665}. Cancer registry data with histological stratification indicate that osteosarcoma is the most common primary malignant tumour of bone, accounting for approximately 35 percent of cases, followed by chondrosarcoma (25%), and Ewing sarcoma (16%). In countries and regions with higher incidence rates, the relative fraction of osteosarcomas appears to be larger. Chordomas and malignant fibrous histiocytoma are much less frequent, constituting approximately 8 and 5% of bone tumours, respectively. In recent years, the diagnosis of fibrosarcoma primary in bone has largely been replaced by that of

malignant fibrous histiocytoma, accounting for a marked decline in the frequency of the former diagnostic category.

Age and site distribution

The age-specific frequencies and incidence rates of bone sarcomas as a group are clearly bimodal. The first well defined peak occurs during the second decade of life, while the second occurs in patients older than sixty. The risk of development of bone sarcomas during the second decade of life is close to that of the older than 60 population, but there are more cases in the second decade. The bimodal age-specific incidence rate pattern of bone sarcomas is clearly different from that of soft tissue sarcomas, which shows a gradual increase of incidence with age.

Osteosarcoma occurs predominantly in patients younger than age twenty, and in this group 80% occur in long bones of the extremities. In this age group, a small proportion of cases involve other parts of the skeleton, such as craniofacial bones, the spine, and pelvis. The clear predilection of osteosarcoma for the appendicu-

lar skeleton has a tendency to decrease with age. In patients older than fifty, osteosarcoma of the extremity bones makes up only 50 % of cases. In this group, the pelvis and craniofacial bones each account for about 20 % of the cases. The incidence rate of extremity bone involvement for patients older than 50 is approximately one third of that for persons in the younger age groups.

Chondrosarcomas have age-specific incidence rates showing a gradual increase up to age 75. The age adjusted rates show little difference by sex and race. More than 50 % of chondrosarcomas occur in the long bones of the extremities. The other major sites of involvement are the pelvis and ribs. The latter site and the sternum are high risk sites for malignant cartilage tumours.

Ewing sarcoma has epidemiological features similar to those of osteosarcoma, but while osteosarcomas tend to occur in the metaphyseal areas of long bones of skeletally immature patients, particularly in the knee region, Ewing sarcoma tends to arise in the diaphysis. The age-specific relative frequency and incidence mir-

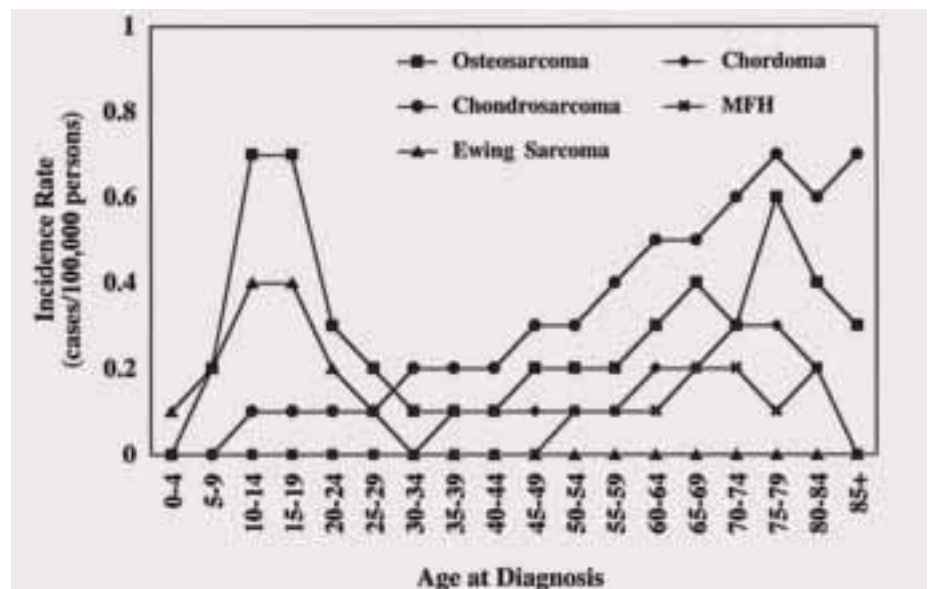


Fig. B.1 Age-specific incidence rates by histological subtype, all races, both sexes, SEER data, 1973-1987. MFH, malignant fibrous histiocytoma and fibrosarcoma.

Relative frequencies of bone sarcomas by histological type, sex, and race: SEER data 1973-1987

Histological type	Total		White		Black	
	No.	%	No.	%	No.	%
Osteosarcoma	922	35.1	743	32.6	106	57.9
Chondrosarcoma	677	25.8	615	27.0	35	19.1
Ewing sarcoma	420	16.0	392	17.3	7	3.8
Chordoma	221	8.4	200	8.8	4	2.2
Malignant fibrous histiocytoma	149	5.7	125	5.5	13	7.1
Angiosarcoma	36	1.4	35	1.5	1	0.5
Unspecified	32	1.2	27	1.2	3	1.6
Other	170	6.4	139	6.1	14	7.8
Total	2627	100.0	2276	100.0	183	100.0

From H. Dorfman & B. Czerniak [537].

ror those of osteosarcoma with the major peak occurring during the second decade of life. Although there is a rapid decrease in incidence after age 20, cases are seen in all age groups. Unlike osteosarcoma, Ewing sarcoma is reported to occur almost exclusively in the white population.

Precursor lesions

Although the majority of primary bone malignancies arise *de novo*, it is increasingly apparent that some develop in association with recognizable precursors. Some of these represent non-neoplastic

Precursors of malignancy in bone

High Risk
Ollier disease (Enchondromatosis) and Maffucci syndrome
Familial retinoblastoma syndrome
Rothmund-Thomson syndrome (RTS)
Moderate Risk
Multiple osteochondromas
Polyostotic Paget disease
Radiation osteitis
Low Risk
Fibrous dysplasia
Bone infarct
Chronic osteomyelitis
Metallic and polyethylene implants
Osteogenesis imperfecta
Giant cell tumour
Osteoblastoma and chondroblastoma

lesions that predispose to malignant transformation. Others are benign neoplasms that can be the source of a malignant neoplastic process. The likelihood of discovering such associated lesions can be facilitated by attention to clinicopathological correlation of all available data before arriving at a diagnosis. In bone, the inclusion of radiographic imaging data in the diagnostic process offers a unique opportunity to discover clues to causal relationships that may not be reflected in histological patterns or in other laboratory data. This is especially true when serial radiographs are available for review.

Paget disease, radiation injury, and some of the more common benign cartilaginous dysplasias are the most clearly established precancerous conditions. Both osteosarcoma and malignant fibrous histiocytoma have been linked to pre-existing condition of bone such as Paget disease, radiation damage, bone infarction, fibrous dysplasia, chronic osteomyelitis, and some genetically determined syndromes {25,132,390,797,867,989,1042,2263}. The relative rarity of malignant transformation in fibrous dysplasia, osteomyelitis, bone cysts, osteogenesis imperfecta, and bone infarction places these conditions in a separate category {540,725,760, 892,1471,2122}.

Aetiology

While radiation and chronic inflammatory states are established, though rare caus-

es of bone malignancies, other exposures and conditions have been suspected (e.g. chromium, nickel, cobalt, aluminum, titanium, methyl-methacrylate, and polyethylene) but not unequivocally confirmed. Recently attention has been focused on a small number of reported cases of bone sarcomas arising in association with implanted metallic hardware and joint prostheses {788, 879, 1083,1683,2225}. However, the epidemiological evidence for a causative role is still limited or inconclusive {6}. Future molecular epidemiological studies in patients who have undergone orthopaedic implantation of metallic and other foreign materials may provide clues to the pathogenetic mechanisms underlying malignant transformation in bone.

Clinical features

The clinical features of bone tumours are non-specific, therefore a long period of time may elapse until the tumour is diagnosed. Pain, swelling and general discomfort are the cardinal symptoms that lead to the diagnosis of bone tumours. However, limited mobility and spontaneous fracture may also be important features.

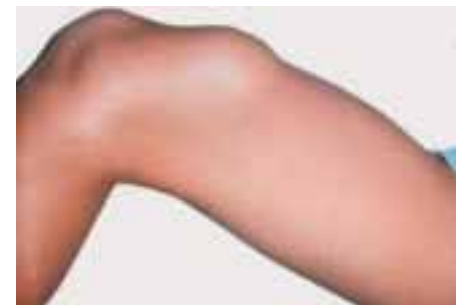

Fig. B.2 Osteochondroma. Hard, smooth, nodular swelling of the distal femur, skin and soft tissues are easily movable and the knee joint is freely mobile.

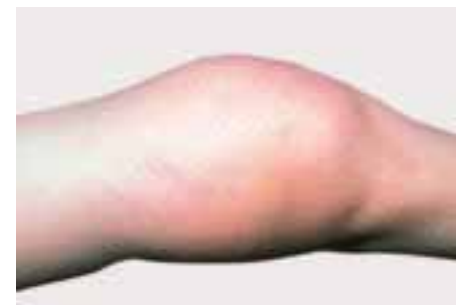

Fig. B.3 Osteosarcoma, causing swelling in the distal femur. Soft tissues poorly movable, consistency ranging from tough to hard, hyperthermia of the skin and marked veins.

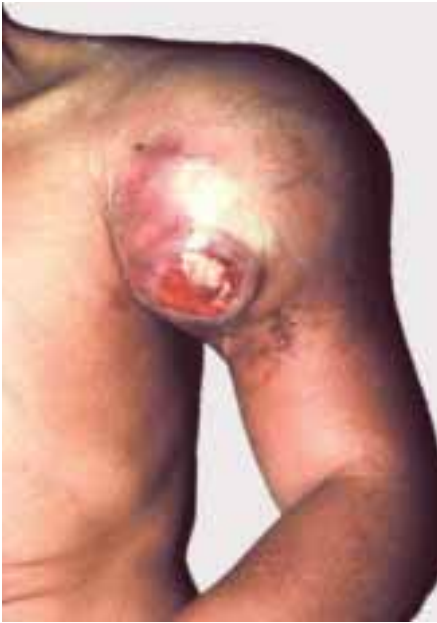

Fig. B.4 Ewing sarcoma of the proximal humerus, presenting as tightly elastic, tense, ulcerated lesion with shining skin, on a grey-white background. Note the marked veins and skin striation.

Pain

Pain is the first and most common symptom in nearly all malignant bone tumours {388,429,1025,1159,1254}. If a spontaneous fracture does not occur, the symptoms usually commence slowly. Initially the patient has tearing neuralgia-like pain, which may also be interpreted as "rheumatic pain". Although the symptoms may initially occur intermittently and only at rest, the pain might subsequently become more intense, disturb sleep at night, spread into the adjacent joint and is frequently misinterpreted as arthritis or as a post-traumatic phenomenon.

A further intensification of pain is experienced as a persistent and piercing pain. During disease progression, the pain becomes excruciating and intolerable, requiring opiate treatment.

In case of pressure on nerve trunks or nerve plexuses, the patient may experience radiating pain. A specific kind of pain occurs when the tumour is located in the spine and causes radicular or spinal compression symptoms with paralysis.

Swelling

The second most important symptom in bone tumours is swelling, which may frequently be of very long duration, especially in benign neoplasms, and cause no

additional complaints. Swelling is only observed if there is an extraosseous part of the tumour or the bone is expanded by the tumorous process. In malignant tumours, swelling develops more rapidly. A description of consistency is important e.g. hard, coarse, tightly elastic or soft. Metric data concerning swelling (in centimeters) should be given; ultrasonic examination may be helpful to establish objective sizes. In advanced stages, tumour swelling may also cause skin changes, including tensed shining skin with prominent veins, livid colouring, hyperthermia, as well as striation of the skin and eventually, ulceration. The mobility of the skin, subcutis and musculature above the tumour should also be assessed. The less the mobility, the more likely is this factor a criterion of malignancy.

Limitation of movement

Mobility may be limited in cases of lesions close to the joint, in tumours such as osteoblastoma, chondroblastoma, giant cell tumours and all types of sarcomas. Occasionally it is not the tumour but reactive synovitis in the joint, especially in chondroblastoma, that causes limitation of movement and masks the true diagnosis.

Pathologic fracture

Fracture is diagnosed early, as it causes the patient to seek attention immediately. It may occur with no prior symptoms at all, as is frequently the case in juvenile cysts and in some non-ossifying bone

fibromas. In cases of malignant bone tumours, fracture is a rather rare primary event, as it usually occurs in advanced stages of osteolytic malignant tumours and the patient will have experienced pain and tumour growth prior to it.

General symptoms

These mainly consist of fever, exhaustion and loss of weight. They are late signs in malignant tumours, and will be absent in nearly all cases of benign bone lesions.

Imaging of bone tumours

Diagnosis

Combining both radiological and histological criteria is most appropriate.

Based on clinical and radiological signs, one should first diagnose benign lesions for which a subsequent biopsy may not be necessary:

- > Metaphyseal fibrous defect
- > Fibrous dysplasia
- > Osteochondroma
- > Enchondroma
- > Simple bone cyst
- > Vertebral haemangioma

Age is useful information: before age of 5, a malignant tumour is often metastatic neuroblastoma; between 5 and 15 years old, osteosarcoma or Ewing sarcoma; and after 40 years, metastasis or myeloma.

The first step is to determine tumour aggressiveness by conventional radiology. Important parameters include tumour

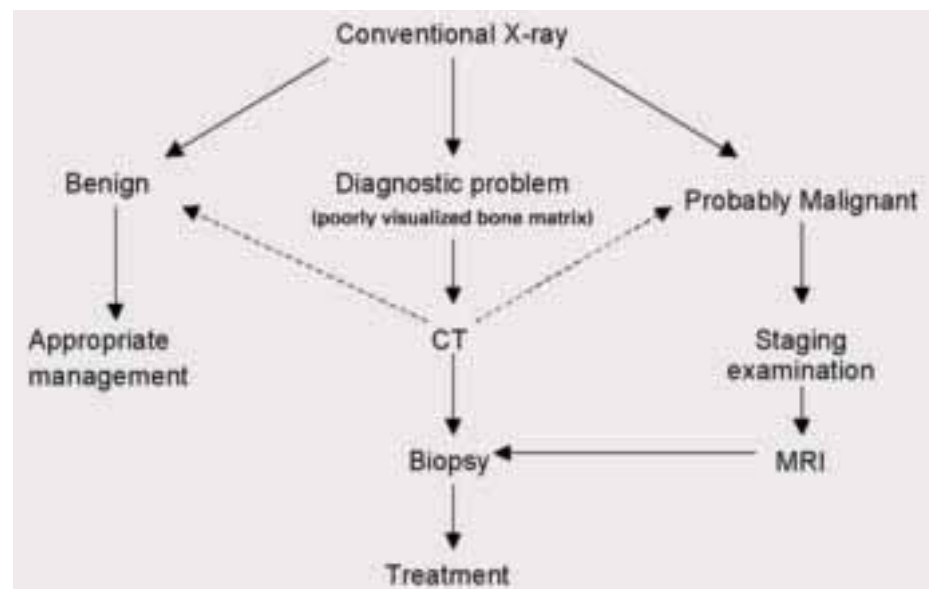


Fig. B.5 The choice of the imaging technique.

TNM Classification of bone tumours

Primary tumour (T)	TX: primary tumour cannot be assessed T0: no evidence of primary tumour T1: tumour ≤ 8 cm in greatest dimension T2: tumour > 8 cm in greatest dimension T3: discontinuous tumours in the primary bone site
--------------------	--

Regional lymph nodes (N)	NX: regional lymph nodes cannot be assessed N0: no regional lymph node metastasis N1: regional lymph node metastasis
--------------------------	--

Note: Regional node involvement is rare and cases in which nodal status is not assessed either clinically or pathologically could be considered N0 instead of NX or pNX.

Distant metastasis (M)	MX: distant metastasis cannot be assessed M0: no distant metastasis M1: distant metastasis M1a: lung M1b: other distant sites
------------------------	---

G Histopathological Grading

Translation table for 'three' and 'four grade' to 'two grade' (low vs. high grade) system

TNM two grade system	Three grade systems	Four grade systems
Low grade	Grade 1	Grade 1 Grade 2
High grade	Grade 2 Grade 3	Grade 3 Grade 4

Note: Ewing sarcoma is classified as high grade.

Stage IA	T1	N0,NX	M0	Low grade
Stage IB	T2	N0,NX	M0	Low grade
Stage IIA	T1	N0,NX	M0	High grade
Stage IIB	T2	N0,NX	M0	High grade
Stage III	T3	N0,NX	M0	Any grade
Stage IVA	Any T	N0,NX	M1a	Any grade
Stage IVB	Any T	N1	Any M	Any grade
	Any T	Any N	M1b	Any grade

From references {831,1979}.

location, size, type of matrix, and periosteal reaction. Certain tumours are more common in particular bones. Adamantinoma, usually found in the adult, selectively involves the tibia and fibula. The most common epiphyseal tumour in childhood is the chondroblastoma. Tumour size is useful and easy to use. A tumour less than 6 cm in greatest dimension is likely benign whereas one

bigger than 6 cm may be benign or malignant. The axis of the lesion is also useful to determine. Tumours are rarely centrally located, such as simple bone cyst. They are most often eccentric. A cortical location is necessary to diagnose a non-ossifying fibroma. Finally the tumour can be a surface lesion.

The next step is to determine the limits of the tumour. The patterns of bone

destruction indicate the aggressiveness of the lesion. Type 1 is the geographic pattern. 1A is characterized by a rim of sclerosis between the normal and lytic area. 1B indicates a very well limited lesion, with sharp separation with normal bone, but no sclerosis. 1C characterizes a less sharp limit. Type 2 is the moth-eaten pattern. It is made of multiple holes separated by not yet destroyed bone and indicates a more aggressive growth. Type 3 is the permeative pattern. Indistinct transition indicates a very rapid progression of the lesion. The pattern of the margins of the tumour only means the rate of progression of the lesion and not directly its malignancy.

Most lesions appear radiolucent on the radiographs but some are sclerotic. The typical arciform calcifications suggest cartilaginous tumours.

The pattern of periosteal new bone formation reacting to the tumour crossing the cortex depends upon the rate of progression of the tumour. When the tumour grows slowly, the periosteum has enough time to build a thick layer of bone. When multiple layers of periosteal formation are present, there is probably a succession of fast and slow growth phases of progression. Perpendicular periosteal formations are a very useful radiological sign, strongly suggesting malignancy.

The Codman's triangle indicates an elevated periosteal reaction, broken by the growth of the tumour. It can be seen in both benign and malignant processes.

Cortical disruption, and soft tissues involvement usually indicate aggressiveness. A thin layer of new bone formation ossified around the tumour suggests a slow evolution and therefore a benign process, even if the cortex is destroyed. On the contrary, tumour on both sides of a not yet destroyed cortex indicates a very aggressive lesion.

Multiple lesions are seen in chondromas, osteochondromas, Langerhans cell histiocytosis, metastases, and more rarely in multifocal osteosarcomas and metastatic Ewing sarcoma.

A flow chart of diagnostic procedures is shown in Fig. B.05. In general, conventional X-ray radiography is the starting point. CT is the examination of choice in the diagnosis of the nidus of osteoid osteoma in dense bone {798}. Small lucency of the cortex, localized involvement of the soft tissues, and thin peripheral periosteal reaction can be seen

Musculoskeletal Tumour Society staging of malignant bone lesions

Stage:	Definition:
IA	Low grade, intracompartmental
IB	Low grade, extracompartmental
IIA	High grade, intracompartmental
IIB	High grade, extracompartmental
III	Any grade, metastatic

Musculoskeletal Tumour Society staging. Surgical margins

Type:	Plane of Dissection:
Intralesional	Within lesion
Marginal	Within reactive zone-extracapsular
Wide	Beyond reactive zone through normal tissue within compartment
Radical	Normal tissue extracompartmental

{279}. CT also allows measurement of the thickness of a non-calcified cuff of a cartilaginous tumour: the cuff is thin in benign lesions and thick (more than 3 cm) in chondrosarcomas {1092}. MRI is rarely useful in the diagnosis, but can display better than CT fluid levels in blood filled cavities, especially aneurysmal bone cysts.

Staging

Focal extent and staging is based on MRI {24,216,222}. The main advantages are high contrast and the possibility of choosing the plane of examination without moving the patient.

Bone metastases are best detected on radionuclide bone scans. Pulmonary metastases are evaluated on conventional chest radiographs and chest CT {2185}. Positron emission tomography (PET) is still under evaluation.

Effectiveness and follow-up of treatment

Most primary malignant tumours are treated with preoperative chemotherapy before removal. Plain films and CT can provide information on the size, margins and ossifications of the tumour. MRI, however, provides a more accurate study of the tumour volume. Signal decrease on T2-weighted sequences suggests in-

creased ossification or more fibrous tissue in the tumour {964}. Lack of increase in signal intensity of the lesion after injection of the contrast agent suggests necrosis. MR imaging with dynamic contrast-enhancement may be useful for differentiating post-chemotherapeutic change from viable tumour, because viable tumour enhances rapidly, and the post-chemotherapeutic changes enhance slowly {463,2175,2202}.

Grading and staging of bone sarcomas

Grading

Histological grading is an attempt to predict the biological behaviour of a malignant tumour based on histological features. The principles used for grading sarcomas are similar to those proposed by Broders for grading of squamous cell carcinoma {272}. In bone tumours, cellularity, i.e., the relative amount of cells compared to matrix, and nuclear features of the tumour cells are the most important criteria used for grading. Generally, the higher the grade, the more cellular the tumour. Irregularity of the nuclear contours, enlargement and hyperchromasia of the nuclei are correlated with grade. Mitotic figures and necrosis are addition-

al features useful in grading {624}.

Spindle cell sarcomas such as osteosarcoma and fibrosarcoma need to be graded. Many studies have shown that histological grading correlates with prognosis in chondrosarcoma and malignant vascular tumours {624,1006,1858}. Tumours which are monomorphic, such as small cell malignancies (Ewing sarcoma, malignant lymphoma and myeloma), do not lend themselves to histological grading. Mesenchymal chondrosarcomas and dedifferentiated chondrosarcomas are always high grade, whereas clear cell chondrosarcomas are low grade. Clinicopathological studies have shown that grading is not useful in predicting prognosis in adamantinoma and chordoma.

The significance of histological grading is limited by inter-observer variability and the fact that the majority of tumours fall into the intermediate range.

Staging

In bone tumours, staging incorporates the degree of differentiation as well as local and distant spread, in order to estimate the prognosis of the patient.

The universal TNM staging system used for most carcinomas is not commonly used for sarcomas because of their rarity with which sarcomas metastasize to lymph nodes. Hence the special staging system adopted by the musculoskeletal society first described by Enneking and co-authors have gained acceptance {2291}. Although staging systems have been described for both benign and malignant bone tumours, the usefulness is primarily in description of malignant bone tumours. Benign lesions are classified using Arabic numerals and malignant ones with Roman numerals. Stage 1 benign lesions are latent lesions having negligible recurrence rate following intracapsular excision. Stage 2 benign lesions are actively growing with a significant recurrence rate after intracapsular procedures but a negligible recurrence rate after marginal en bloc excision. Stage 3 benign lesions are locally aggressive with extracapsular extension having a high recurrence rate after either intracapsular or marginal procedures.

A surgical staging system for malignant lesions is most logically accomplished with the assessment of the surgical grade (G), the local extent (T), and the presence or absence of regional or dis-

tant metastases (M). Any neoplasm can be divided into two grades; low (G1) and high (G2). In general, low grade lesions correspond to Broders grade 1 and 2 and have less than 25% risk of metasta-

sis. High grade lesions (Broders grade 3 and grade 4) have a great risk of local recurrence and greater than 25% risk of distant spread. The anatomic extent (T) is subdivided according to whether the

lesion is intracompartmental (A) or extra-compartmental (B) {55, 1677}. The presence or absence of metastasis (M) is the third major factor related to both prognosis and surgical planning.